VII CONGRESO SEICAV
Sociedad Española de Infecciones Cardiovasculares
SEVILLA 16 Y 17 DE NOVIEMBRE DE 2018
10 Años
Grupos de Apoyo al Manejo de la Endocarditis Infecciosa en España
Con todo el corazón

Caso Clínico 2

Infección en prótesis vascular

Dolores Sousa
Enfermedades Infecciosas
Complexo Hospitalario A Coruña

Contemporánea
PREMIO NOBEL DE LITERATURA
GABRIEL GARCÍA MÁRQUEZ
Crónica de una muerte anunciada
DEBOLSILLO

Antecedentes Personales:

85 años,

- Alergias: No
- Cardiopatía isquémica crónica estable
- Bronquitis crónica. NAC (2014) que requirió VMNI
- Adenocarcinoma de próstata Gleason 9 (2016) en tto con hormonoterapia, sin evidencia de enfermedad a distancia
- AAA infrarrenal→ **EVAS: endoprótesis Nellix stent dcho e izdo (12/06/2017)**
- Vida basal: medio urbano, cognitivamente intacto, independiente.

Enfermedad Actual:

- 09/05/2018 → Presenta Tª 39ºC, sin foco.
- 09/05/2018 → Hemocultivos positivos (2/2):
- Inicio de tto con ertapenem

Estudio de Sensibilidad Mostra: **Sangue via periférica**
Illase

Streptococcus intermedius (1)

Antibióticos	(1)
Amoxicilina/acido clavulanico	**Sensible(<=0.5/.2)**
Ceftriaxona	**Sensible(<=0.25)**
Clindamicina	**Sensible(<=0.06)**
Cefotaxima	**Sensible(<=0.25)**
Cefepima	**Sensible(<=0.25)**
Eritromicina	**Sensible(<=0.06)**
Levofloxacino	**Sensible(<=0.25)**
Meropenem	**Sensible(<=0.06)**
Penicilina	**Sensible(<=0.03)**

¿Cree que el paciente presenta una infección protésica vascular?

No en este momento.

Se trata de un EVAS que se infectaría excepcionalmente.

No lo creo.

La etiología más frecuente de los stents/endoprótesis vasculares es la estafilocócica

NO. Descartaría EI.

Solicitaría un ecocardiograma como prueba inicial

Sí lo sospecho.

Solicitaría un TC abdominal/PET-TC como prueba inicial

¿Cree que el paciente presenta una infección protésica vascular?

Sí lo sospecho.

Solicitaría un TC abdominal/PET-TC como prueba inicial

EVAS

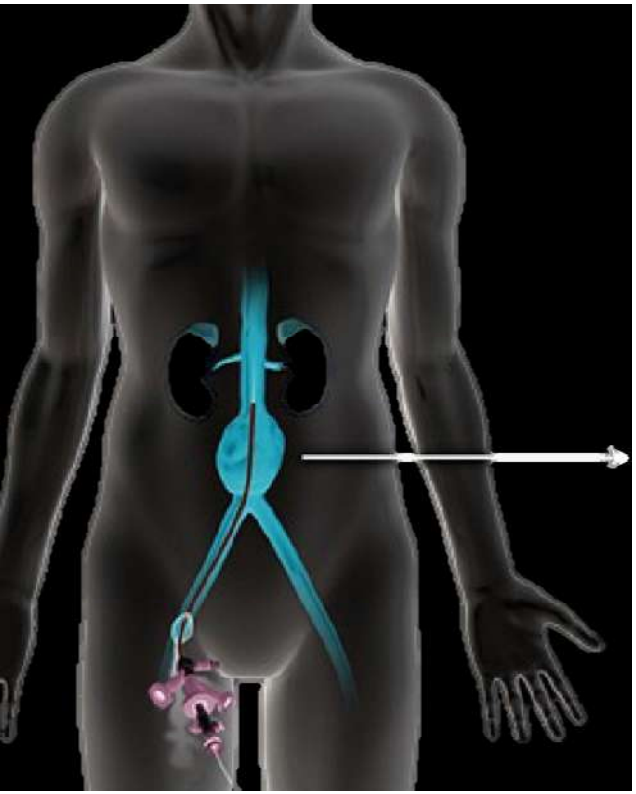

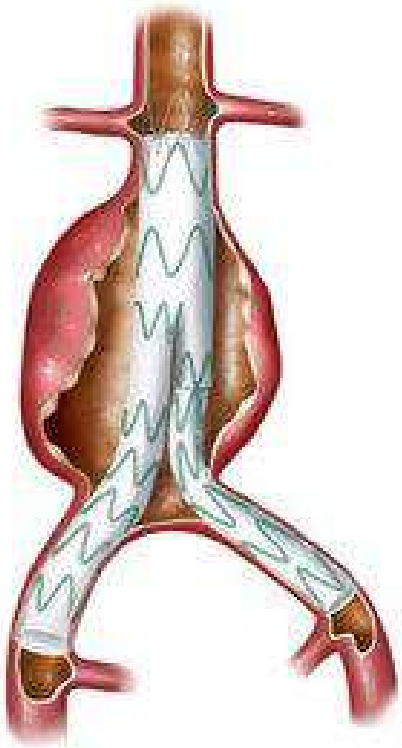



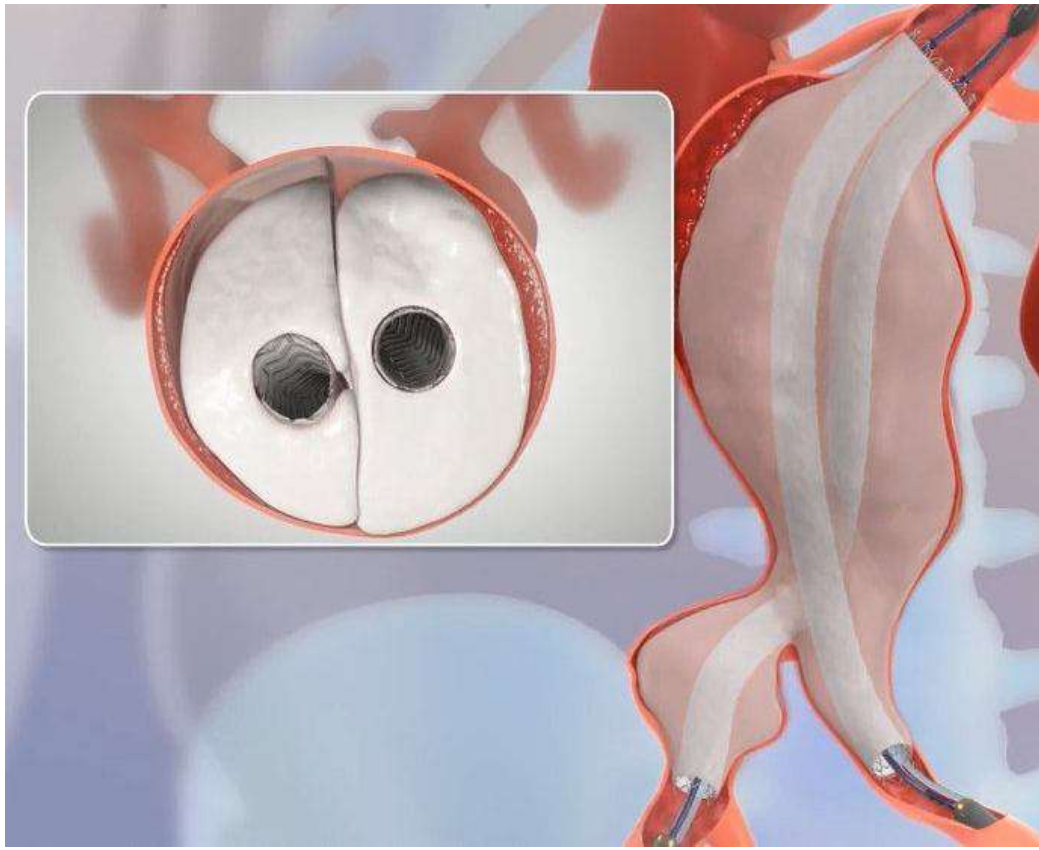

Diagnosis of Aortic Graft Infection: A Case Definition by the Management of Aortic Graft Infection Collaboration (MAGIC)

O.T.A. Lyons [a,b], M. Baguneid [c,d], T.D. Barwick [e,f], R.E. Bell [a], N. Foster [g], S. Homer-Vanniasinkam [h,i], S. Hopkins [j], A. Hussain [k,l], K. Katsanos [m,n], B. Modarai [a,b], J.A.T. Sandoe [g,o], S. Thomas [p], N.M. Price [q,*]

Criterios mayores

Criterios menores

→ Clínicos/Quirúrgicos

→ Radiológicos

→ Laboratorio

- Sospecha de infección:
  - 1M
  - 2m
- Diagnóstico de infección:
  - 1M + 1 de ≠categoría

Eur J Vasc Endovasc Surg (2016) 52, 75

	CLINICAL / SURGICAL	RADIOLOGY	LABORATORY
MAJOR CRITERIA	• Pus (confirmed by microscopy) around graft or in aneurysm sac at surgery • Open wound with exposed graft or communicating sinus • Fistula development e.g. aorto-enteric or aorto-bronchial • Graft insertion in an infected site e.g. fistula, mycotic aneurysm or infected pseudoaneurysm	• Peri-graft fluid on CT scan ≥ 3 months after insertion • Peri-graft gas on CT scan ≥ 7 weeks after insertion • Increase in peri-graft gas volume demonstrated on serial imaging	• Organisms recovered from an explanted graft • Organisms recovered from an intra-operative specimen • Organisms recovered from a percutaneous, radiologically-guided aspirate of peri-graft fluid
MINOR CRITERIA	• Localized clinical features of AGI e.g. erythema, warmth, swelling, purulent discharge, pain •	• Other e.g. suspicious peri-graft gas/fluid/soft tissue inflammation; aneurysm expansion; pseudoaneurysm formation; focal bowel wall thickening; discitis/ osteomyelitis; suspicious metabolic activity on FDG PET/ CT; radiolabelled leukocyte uptake	• • Abnormally elevated inflammatory markers with AGI as most likely cause e.g. ESR, CRP, white cell count

Eur J Vasc Endovasc Surg (2016) 52, 75

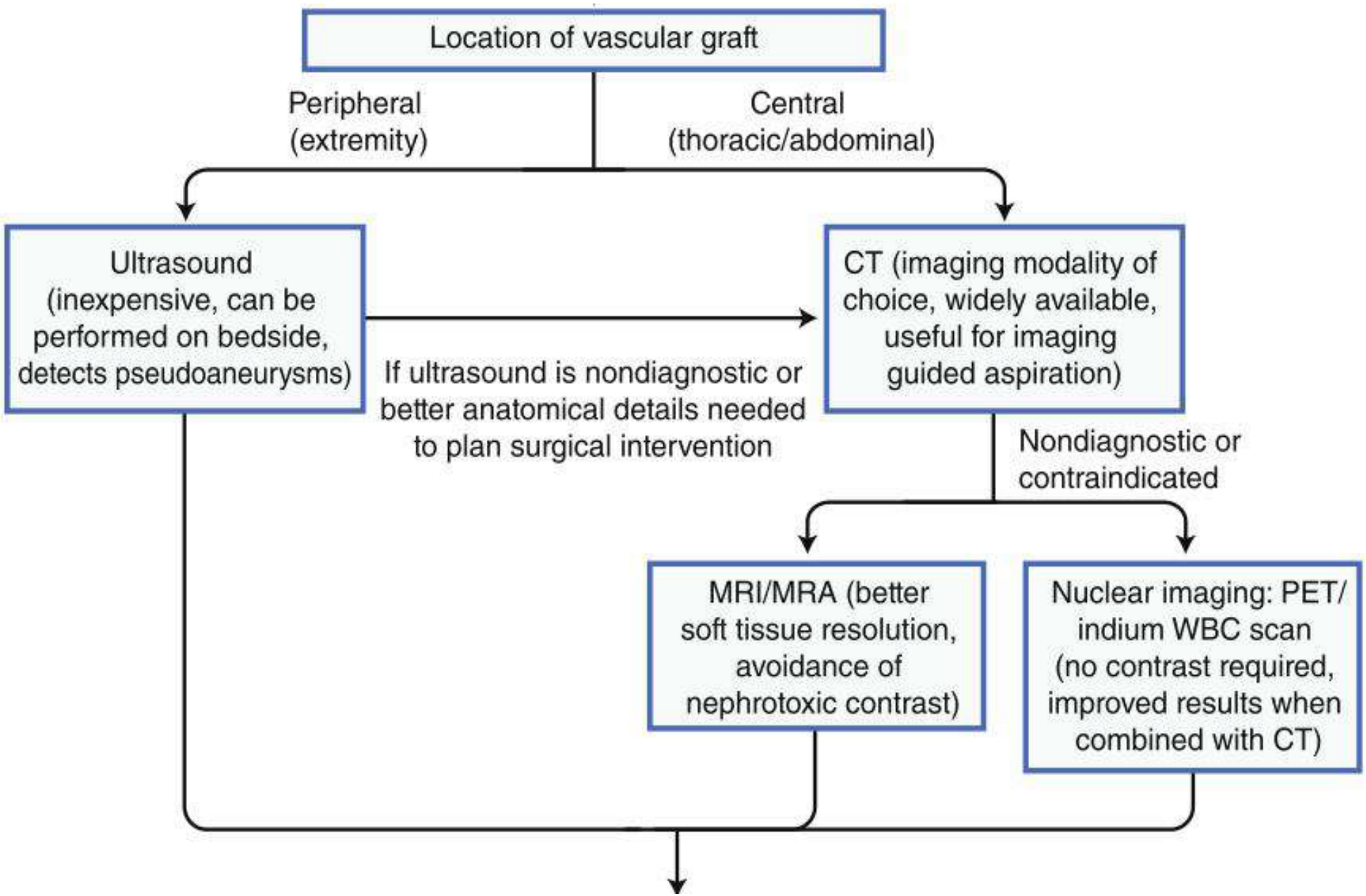

Nagpal, Curr Infect Dis Rep (2011), 13:31

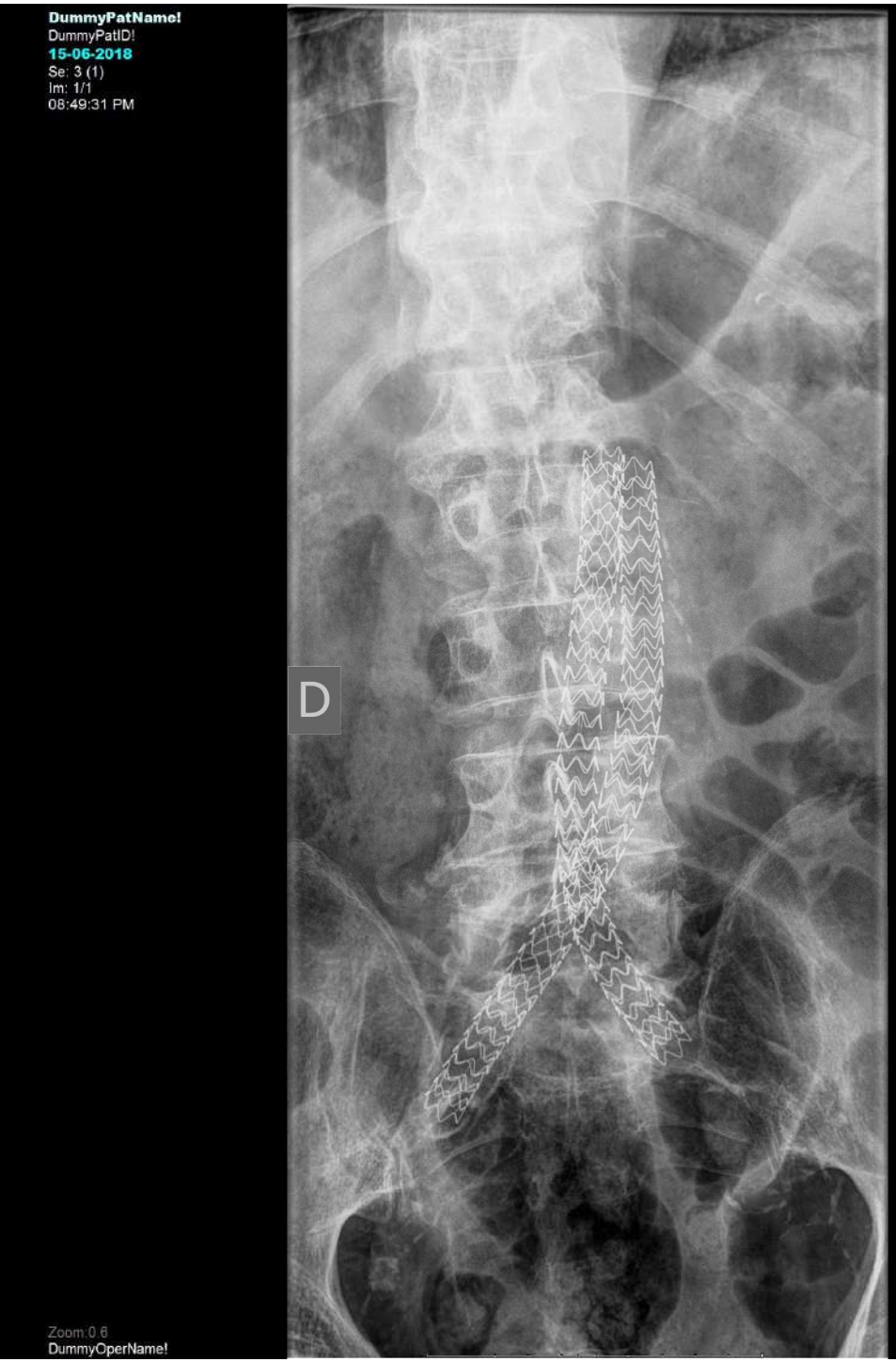
DummyPatName!
DummyPatID!
15-06-2018
Se: 3 (1)
Im: 1/1
08:49:31 PM
D
Zoom:0.6
DummyOperName!

DummyPatName!
DummyPatID!
15-06-2018
Se: 5 (1)
Im: 1/1
08:58:51 PM
Zoom:0.6
DummyOperName!

21/05/2018

28/05/2018

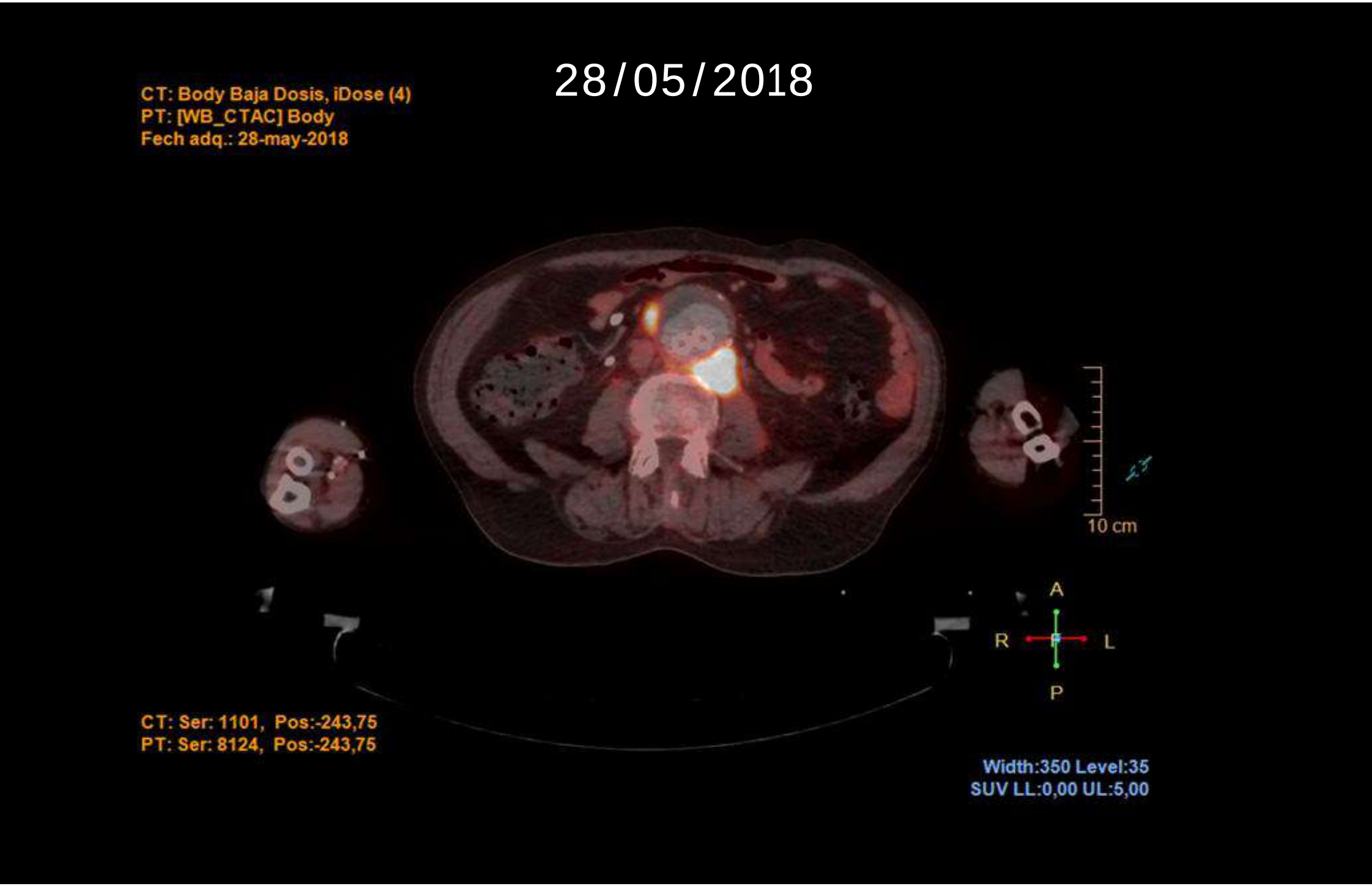
CT: Body Baja Dosis, iDose (4)
PT: [WB_CTAC] Body
Fech adq.: 28-may-2018
10 cm
A
R
L
P
CT: Ser: 1101, Pos:-243,75
PT: Ser: 8124, Pos:-243,75
Width:350 Level:35
SUV LL:0,00 UL:5,00

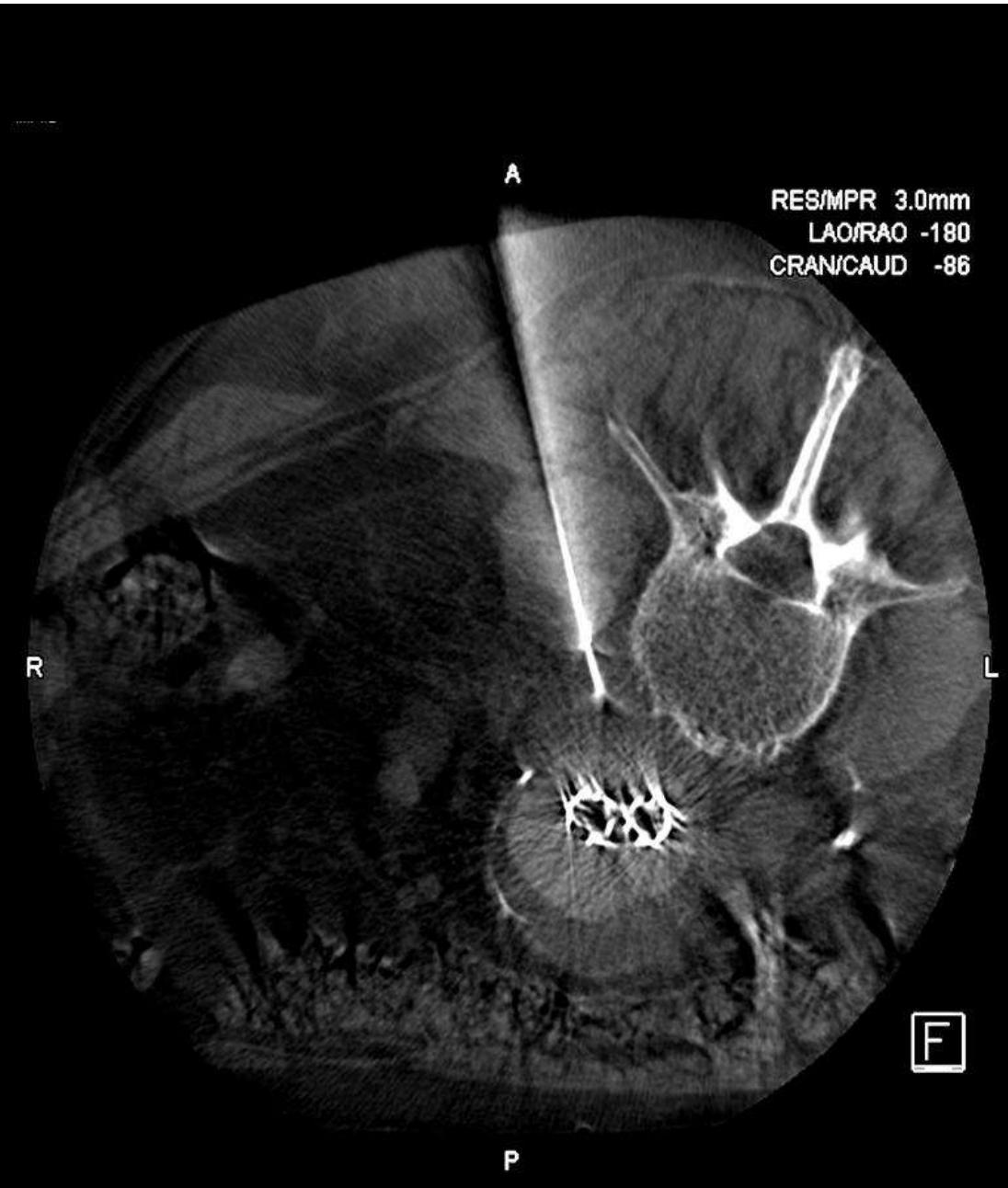

28/05/2018

- Drenaje colección: contenido hemato-purulento
- Cultivo: *S. intermedius*

	CLINICAL / SURGICAL	RADIOLOGY	LABORATORY
MAJOR CRITERIA	• Pus (confirmed by microscopy) around graft or in aneurysm sac at surgery • Open wound with exposed graft or communicating sinus • Fistula development e.g. aorto-enteric or aorto-bronchial • Graft insertion in an infected site e.g. fistula, mycotic aneurysm or infected pseudoaneurysm	• • Peri-graft gas on CT scan ≥ 7 weeks after insertion • Increase in peri-graft gas volume demonstrated on serial imaging	• Organisms recovered from an explanted graft • Organisms recovered from an intra-operative specimen •
MINOR CRITERIA	• Localized clinical features of AGI e.g. erythema, warmth, swelling, purulent discharge, pain •	• Other e.g. suspicious peri-graft gas/fluid/soft tissue inflammation; aneurysm expansion; pseudoaneurysm formation; focal bowel wall thickening; discitis/ osteomyelitis; suspicious CT; radiolabelled leukocyte uptake	• • Abnormally elevated inflammatory markers with AGI as most likely cause e.g. ESR, CRP, white cell count

Eur J Vasc Endovasc Surg (2016) 52, 758

¿Qué tratamiento AB indicaría después de la punción del absceso?

Continuaría ertapenem por la sospecha de infección polimicrobiana

Aumentaría el espectro antimicrobiano para cubrir microorganismos resistentes

Añadiría rifampicina

Ajustaría a penicilina

¿Qué tratamiento AB indicaría después de la punción del absceso?

Continuaría ertapenem por la sospecha de infección polimicrobiana

able 1. Baseline Clinical Characteristics.

rst Author, ear	N	Microbiology[b]
haufour, 2016[15]	33	G^+ (55)
neds, 2016[21]	180	G^+ (~22); G^- (~13); fungi (~5); polymicrobial (~35)
avila, 2015[22]	36	G^+ (67); G^- (17); fungi (14); anaerobes (17)
apoccia, 2015[23]	26	G^+ (20); G^- (23); fungi (16)
urney, 2014[24]	13	NR
enna, 2014[25]	12	NR
ons, 2013[26]	13	NR
rya, 2013[13]	12	G^+ (25); G^- (33);
ser, 2011[16]	9	G^+ (33); G^- (44); fungi (11)
nade, 2011[8]	6	NR
eyer, 2009[27]	5	G^+ (100)
arif, 2007[28]	6	G^+ (67)

JOURNAL OF ENDOVASCU TH
ISEVS
Journal of Endovascular Th
2017, Vol. 24(5) 688–697
© The Author(s) 2017
Reprints and permissions:
sagepub.com/journalsPerm
DOI: 10.1177/1526602817
www.jevt.org
SAGE

Endograft Infection After Endovascular Abdominal Aortic Aneurysm Repair: A Systematic Review and Meta-analysis

Christos Argyriou, MD, PhD[1], George S. Georgiadis, MD, PhD[1], Miltos K. Lazarides, MD, PhD, FEBVS[1], Efstratios Georgakarakos, MD, PhD, MSc[1], and George A. Antoniou, MD, PhD, MSc, FEBVS[2]

12 studies: 362 EVAR

Year: 2007-2016

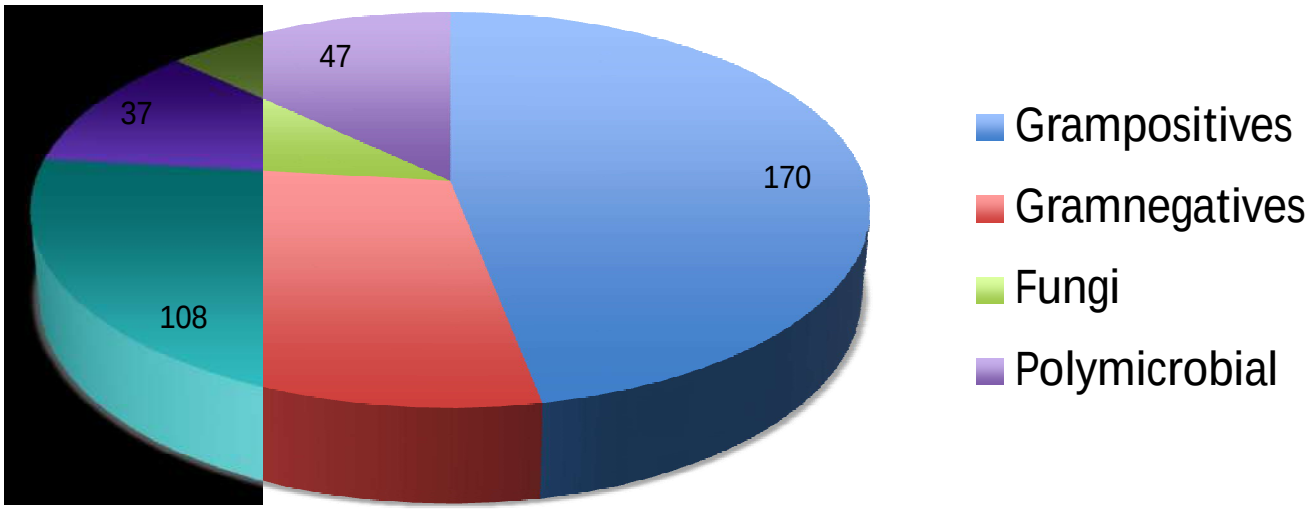

Treatment and outcomes of aortic endograft infection

Matthew R. Smeds, MD,[a] Audra A. Duncan, MD,[b] Michael P. Harlander-Locke, MPH,[c] Peter F. Lawrence, MD,[d] Sean Lyden, MD,[e] Javariah Fatima, MD,[f] and Mark K. Eskandari, MD,[g] on behalf of the Vascular Low-Frequency Disease Consortium, *Little Rock, Ark; Rochester, Minn; Bradenton and Gainesville, Fla; Los Angeles, Calif; Cleveland, Ohio; and Chicago, Ill*

ulti-insitutional
(2004-2014)

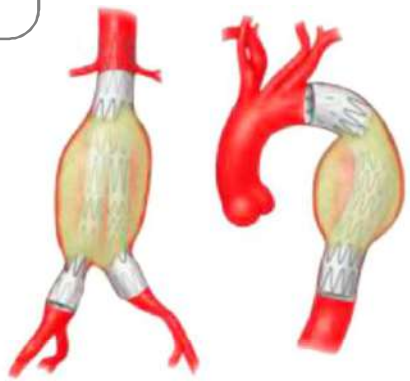

AEF (27%)

206 Patients
180 EVAR
26 TEVAR

Surgery
197 Patients (97%)
176 EVAR
21 TEVAR

Medical
9 Patients (3%)
4 EVAR
5 TEVAR

Negative cultures (30%)
Polymicrobial (35%)
Hemocultivos + (63%)

G+ (22%)
↓
Streptococcus spp
(most prevalent)

Journal of Vascular Surgery 2016 63, 332-340DOI: (10.1016/j.jvs.2015.08.113)
Copyright © 2016 Society for Vascular Surgery Terms and Conditions

m the Society for Vascular Surgery

multicenter experience with infected abdominal rtic endograft explantation

er Chaufour, MD, PhD,[a] Julien Gaudric, MD,[b] Yann Goueffic, MD, PhD,[c] Réda Hassen Khodja, MD,[d]
rick Feugier, MD, PhD,[e] Sergei Malikov, MD,[f] Guillaume Beraud, MD, PhD,[g] *and*
n-Baptiste Ricco, MD, PhD,[h] for the AURC (French University Surgeons Association) collaborators,*
ouse, Paris, Nantes, Nice, Lyon, Nancy, and Poitiers, France

Table III. Microbiology of infected endografts

Variables	Cultures (N = 37[a])
Organisms	
Sterile	9
Staphylococcus aureus (4), *S. epidermidis* (5)	9
Streptococcus	5
Enterococcus	4
Gram-negative (*Escherichia coli, Serratia, Proteus, Salmonella*)	6
Anaerobes (*Bacteroides fragilis*)	2
Candida (fungus)	2
Patients with polymicrobial cultures	4

[a]There were 28 organisms found in 24 patients with a positive culture. Four patients had two bacteria found in the endograft or in the aortic aneurysm.

11 French Centres (1998-2015)

33 iEVAR explanted

AEF: 36%

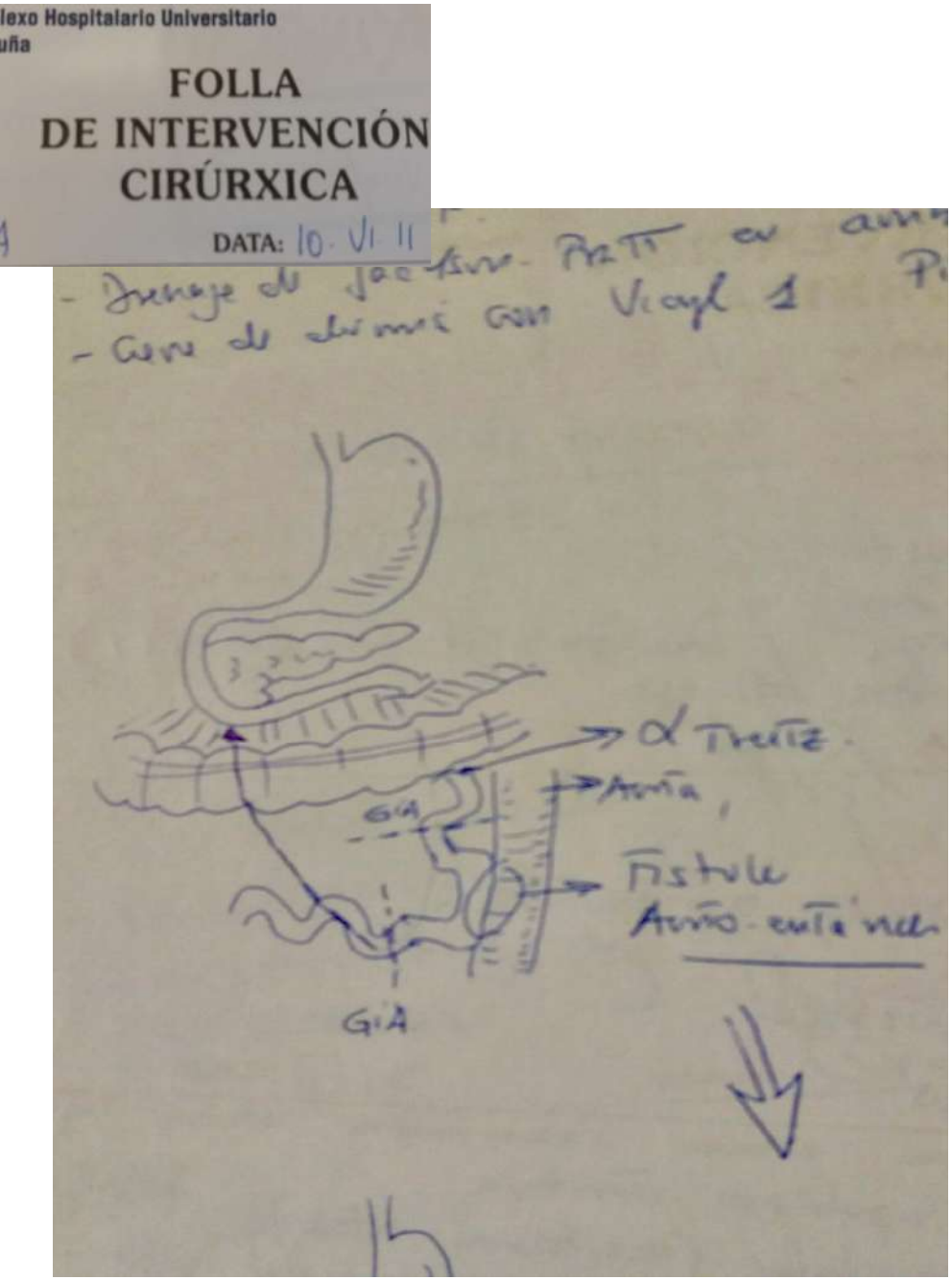

Fístulas aortoentéricas secundarias: características clínicas y microorganismos causales

Microorganismo	Número (%)
Streptococcus spp.	17 (23.0)
Staphylococcus spp.	4 (5.4)
Enterococcus spp.	3 (4.1)
Escherichia coli	8 (10.8)
Enterobacterias del grupo 3	4 (5.5)
Klebsiella spp.	2 (2.7)
Pseudomonas spp.	2 (2.7)
Anaerobios	23 (31.3)
Grampositivos	7 (9.5)
Bacteroides spp.	3 (4.1)
Otros gramnegativos	13 (17.6)
Candida spp.	6 (8.1)
Polimicrobiano	(61)

Tabla 1. Microorganismos más frecuentes aislados globalmente

Junio 2017

Mayo

Aneurisma Ao abdominal

Endoprótesis Nellix

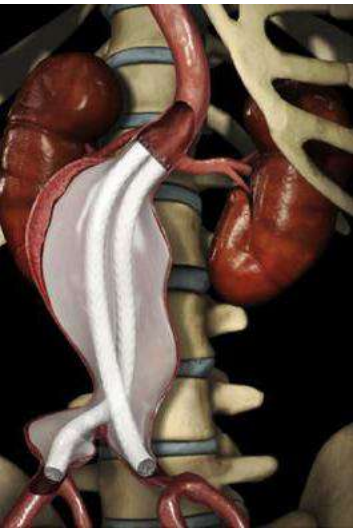

09/05/2018
Síndrome febril
Bacteriemia *S. intermedius*
Ertapenem

28/05/2018
PET-TC positivo
Punción colección periaórtica
Cultivo local: *S. intermedius*

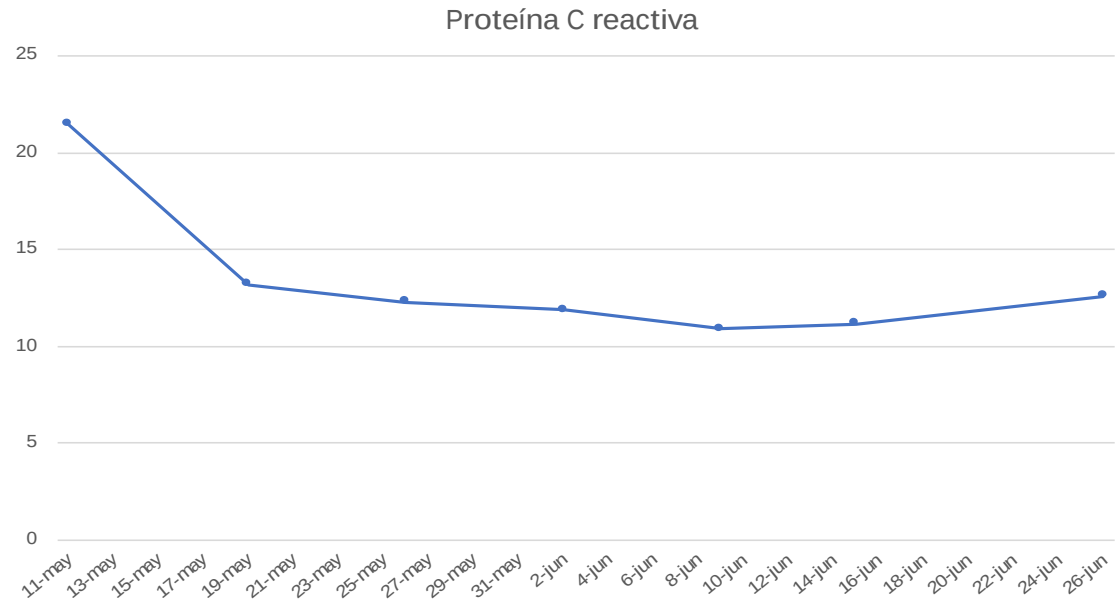

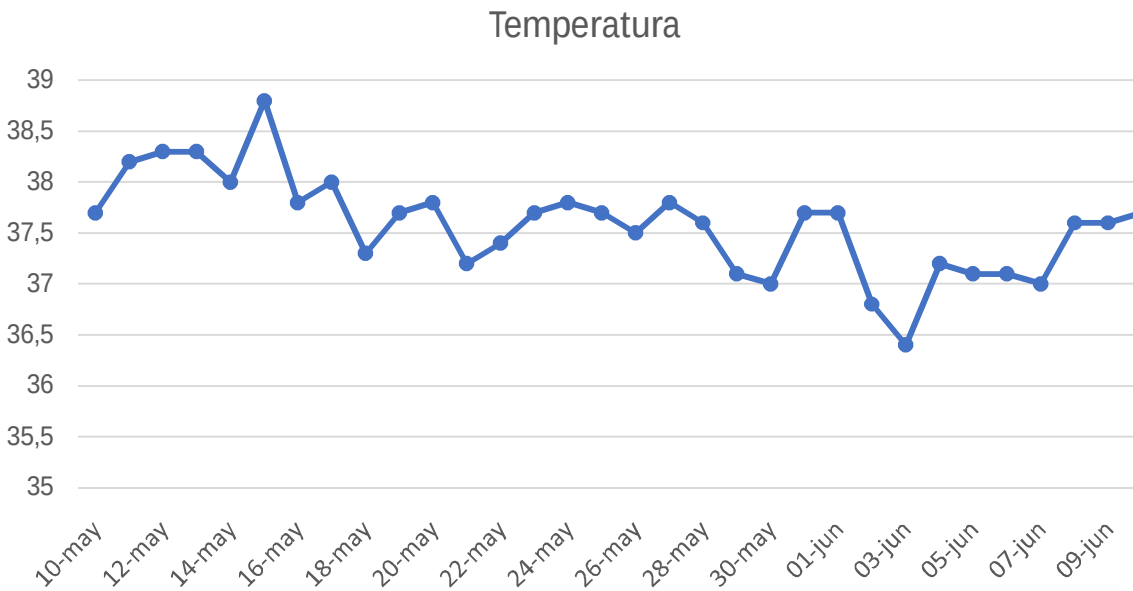

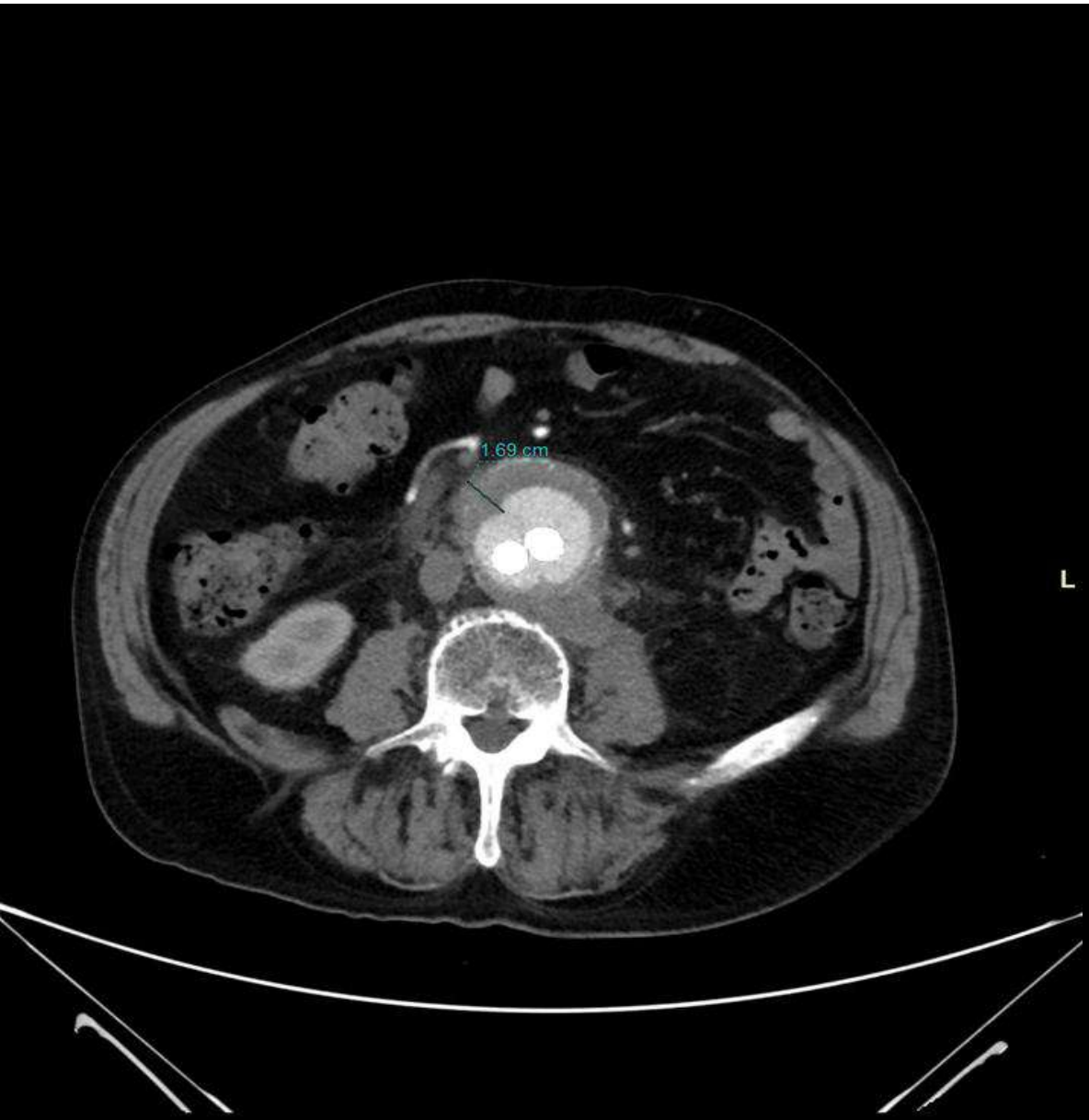

08/06/2018

- Aortitis
- Colección lateral dcha
- Aumento tamaño colecció
  periprotésica post-lat izq

19/06/2018

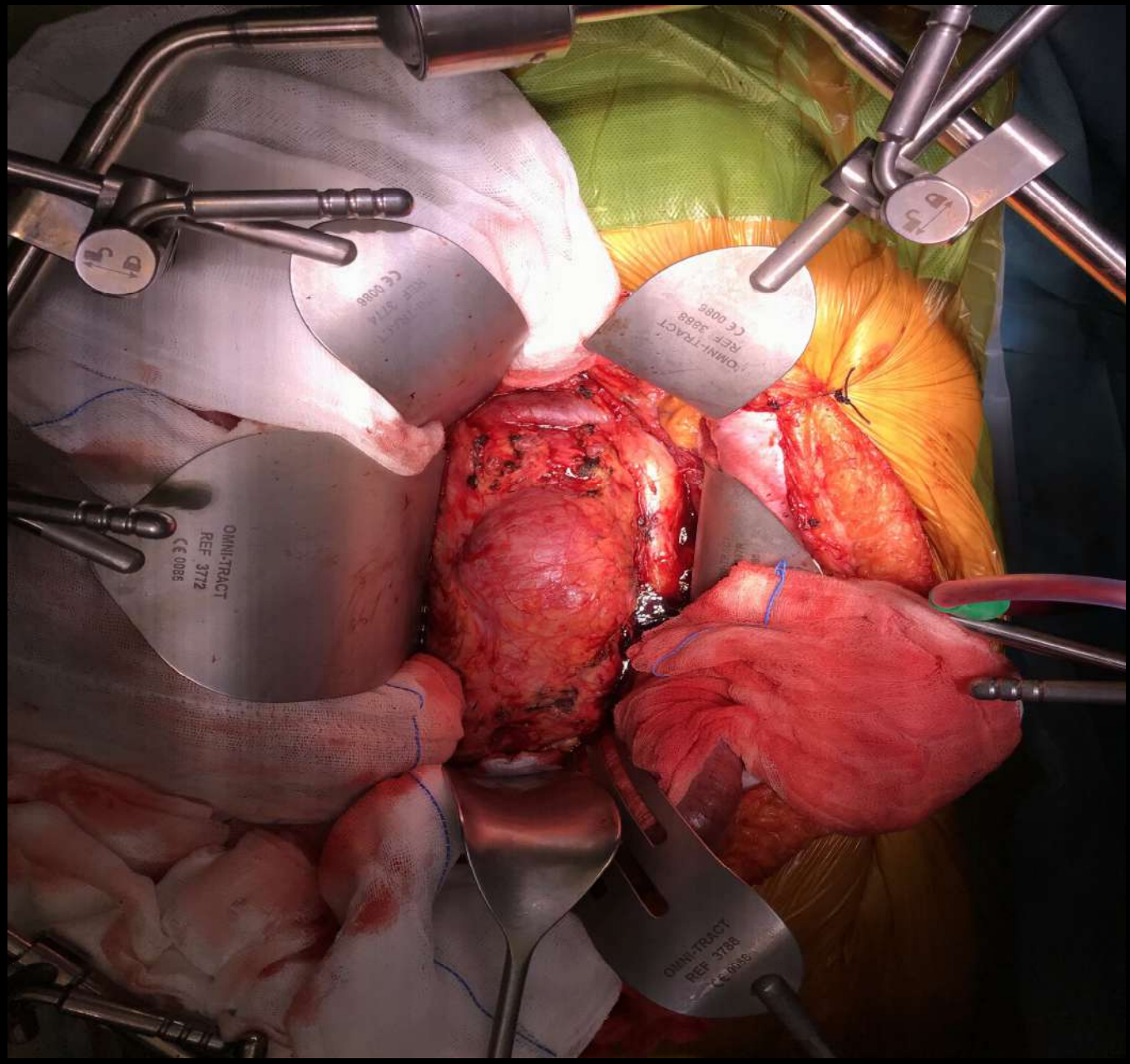
OMNI-TRACT
REF 3772
CE 0086
OMNI-TRACT
REF 3888
CE 0086
OMNI-TRACT
REF 3738
CE 0086

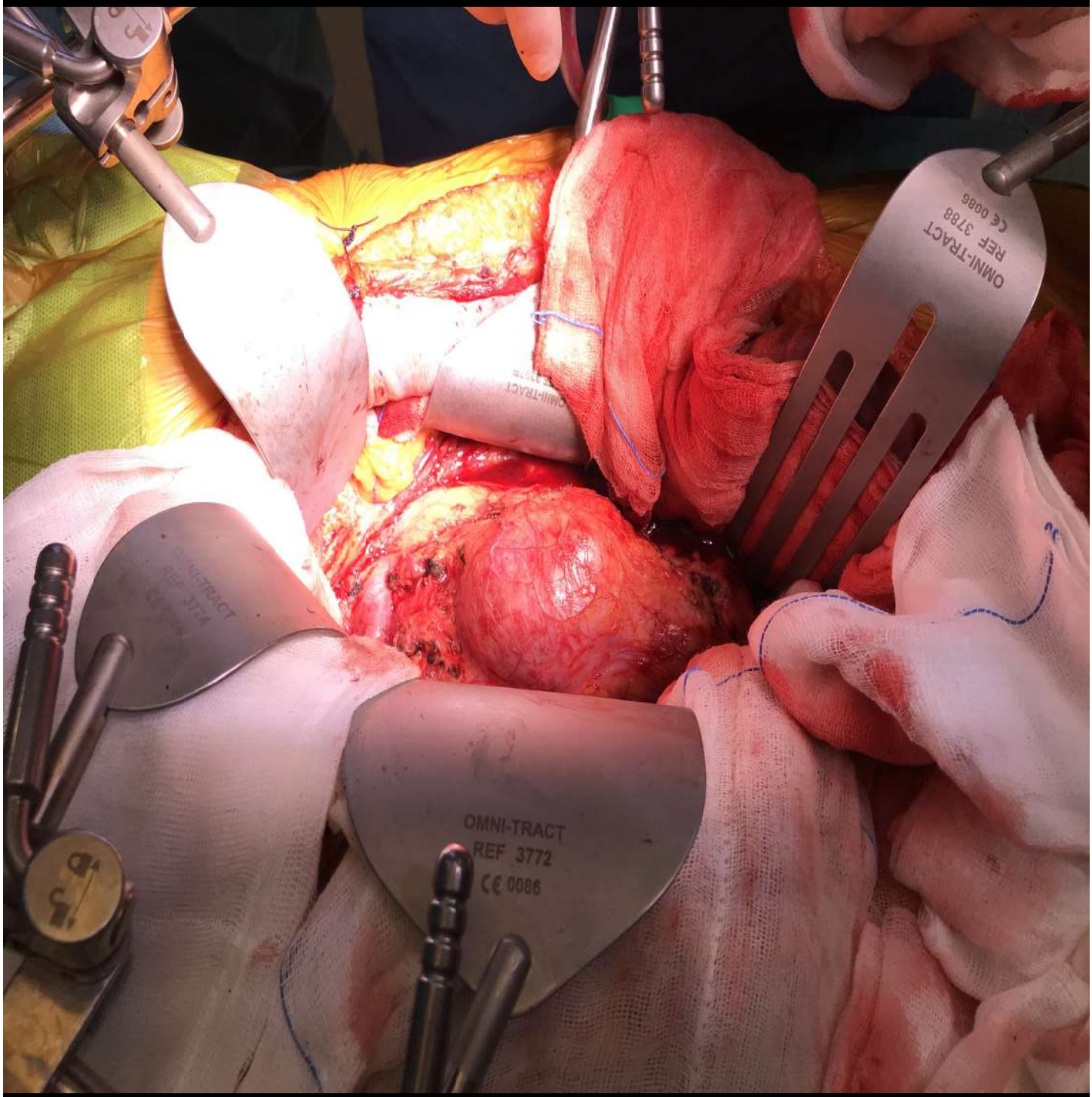
OMNI-TRACT
REF 3772
CE 0086
OMNI-TRACT
REF 3788
CE 0086

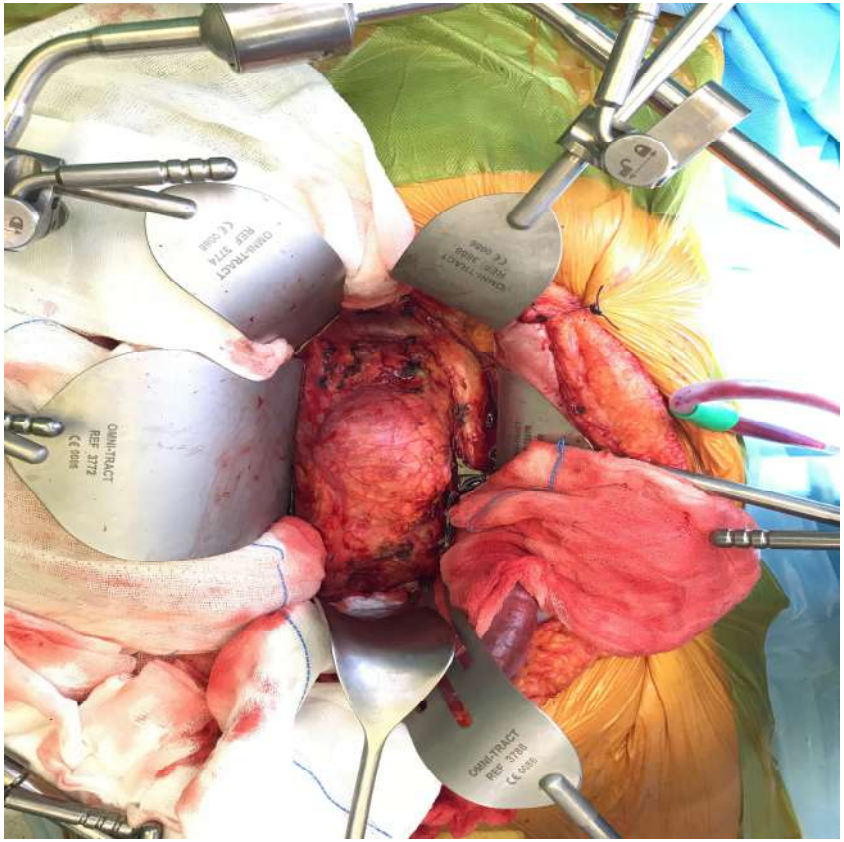

Microb:

- Conglomerado adenopático peri-Ao: negativo
- Tej. periprotésico (x2): negativo

¿Actitud terapéutica?

Conservadora.

El cirujano descarta infección.

Si cultivos io neg., suspender AB

Actitud quirúrgica.

Explante EVAS y BP in situ

Conservadora.

Completar tto de inducción y tratamiento supresivo vo de por vida

Actitud quirúrgica.

Explante EVAS y BP extra-anatómico

¿Actitud terapéutica?

Conservadora.

Completar tto de inducción y tratamiento supresivo vo de por vida

Current Evidence on Management of Aortic Stent-graft Infection: A Systematic Review and Meta-Analysis

Hai Lei Li,[1] Yiu Che Chan,[2] and Stephen W. Cheng,[2] Guangdong and Hong Kong, China

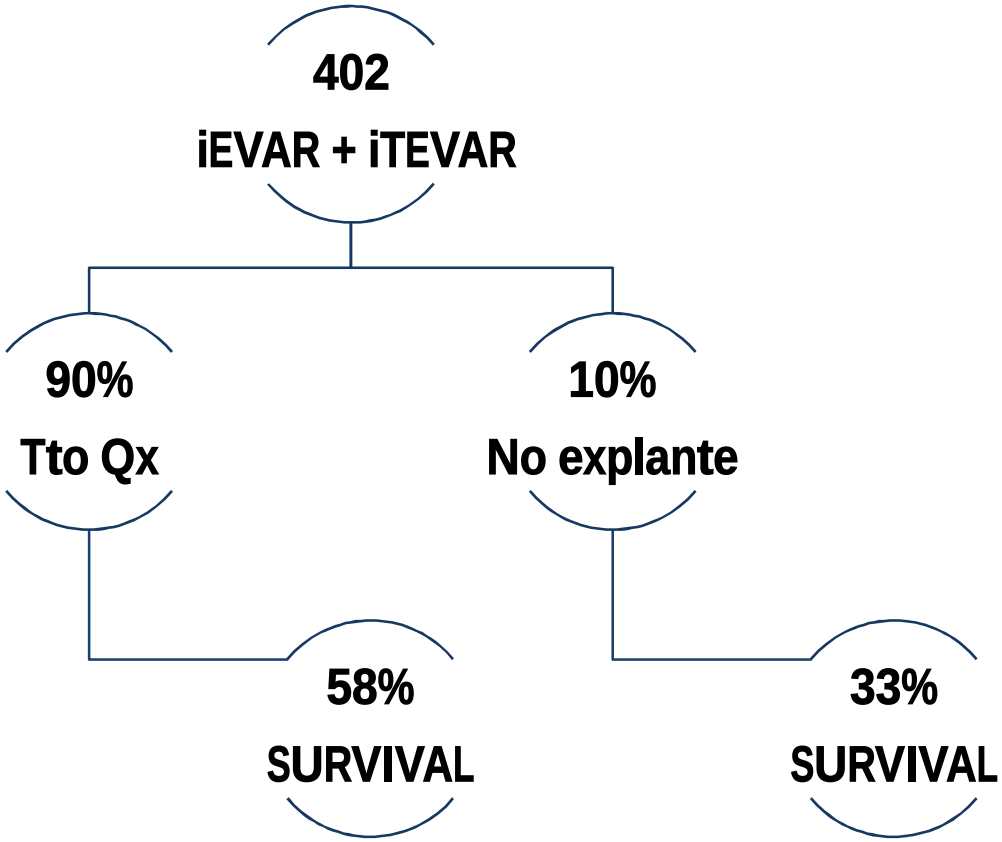

P=002

Ann Vasc Surg 2018; 51: 306–313
https://doi.org/10.1016/j.avsg.2018.02.038
© 2018 Elsevier Inc. All rights reserved.

A multicenter experience with infected abdominal aortic endograft explantation

avier Chaufour, MD, PhD,[a]

Mortalidad peri-operatoria: 39%

Supervivencia a 1 año: 44%

able V. Causes of death at 30 days or in the hospital after emoval of the infected endograft

Causes of death	Patients	Time, days
New graft rupture	3	2, 20, 40
Cryopreserved aortic allograft	2	2, 20
Autogenous femoral vein	1	40
epsis (multiple organ failure)[a]	6	2, 2, 12, 15, 45, 56
Colon necrosis[b]	3	5, 5, 15
ower limb ischemia[c]	1	30

Two reoperations for recurrent aortic sepsis.
Three colectomies.
Bilateral trash foot, patient refused major amputation.

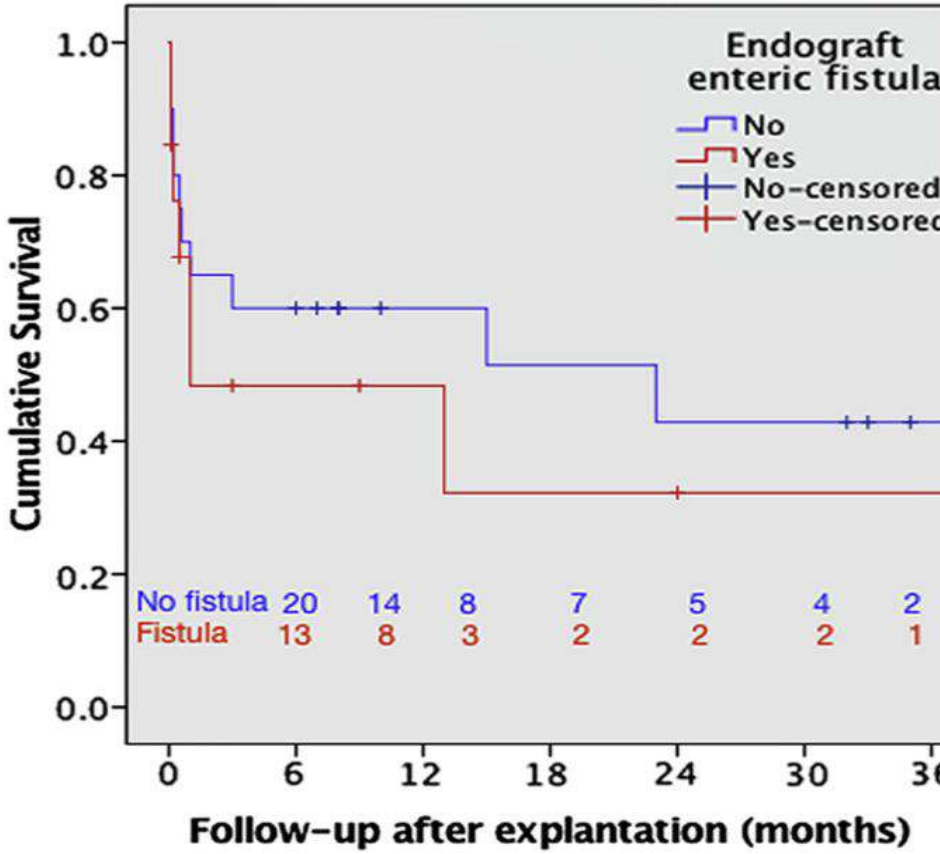

c Surg 2017;65:372-80.

Treatment and outcomes of aortic endograft infection

Matthew R. Smeds, MD,[a]

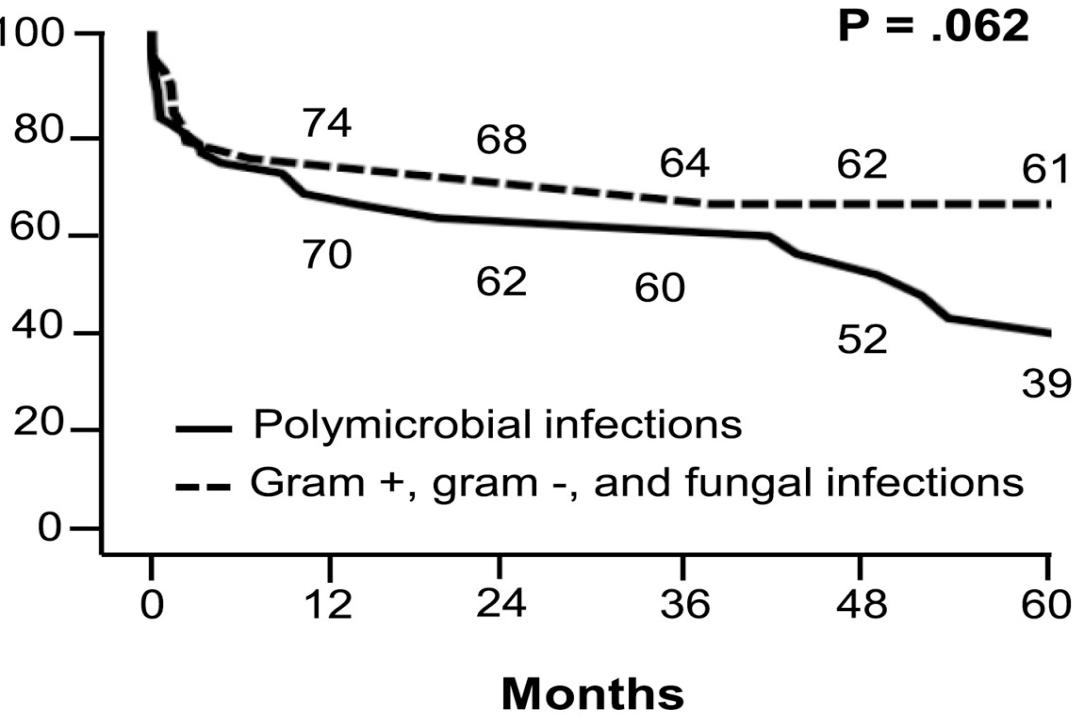

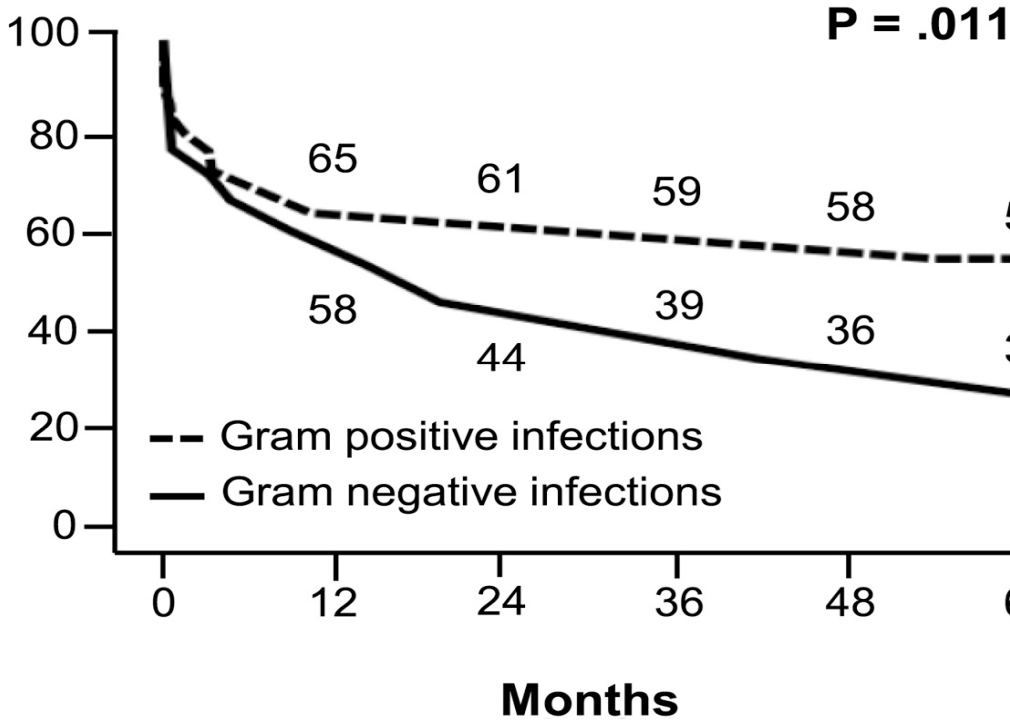

Journal of Vascular Surgery 2016 63, 332-340DOI: (10.1016/j.jvs.2015.08.113)
Copyright © 2016 Society for Vascular Surgery Terms and Conditions

ascular Graft Infections

n update

al Gharamti, MD[a], Zeina A. Kanafani, MD, MS, CIC[a,b,*]

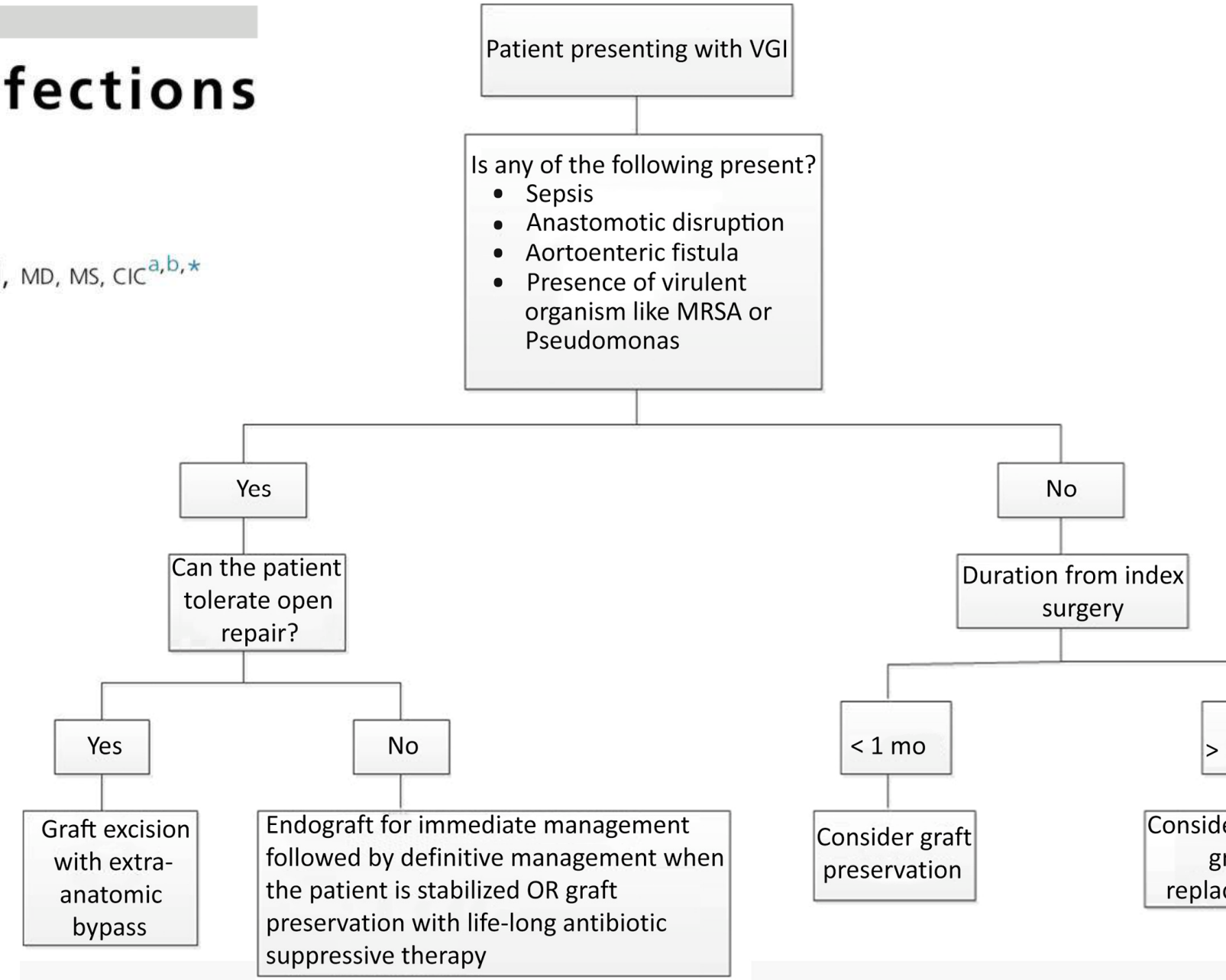

Dis Clin N Am ■ (2018) ■–■
/doi.org/10.1016/j.idc.2018.06.003
520/18/© 2018 Elsevier Inc. All rights reserved.

Nuestro paciente:

Tratamiento conservador.

Premisas mejor pronóstico:

- Ausencia de FAE
- Baja carga bacteriana. Drenaje de colecciones
- Riesgo quirúrgico alto para el explante (iEVAR)
- Infección monomicrobiana por microorganismo grampositivo
- Edad avanzada. Posibilidad de TAS

Nuestro paciente:

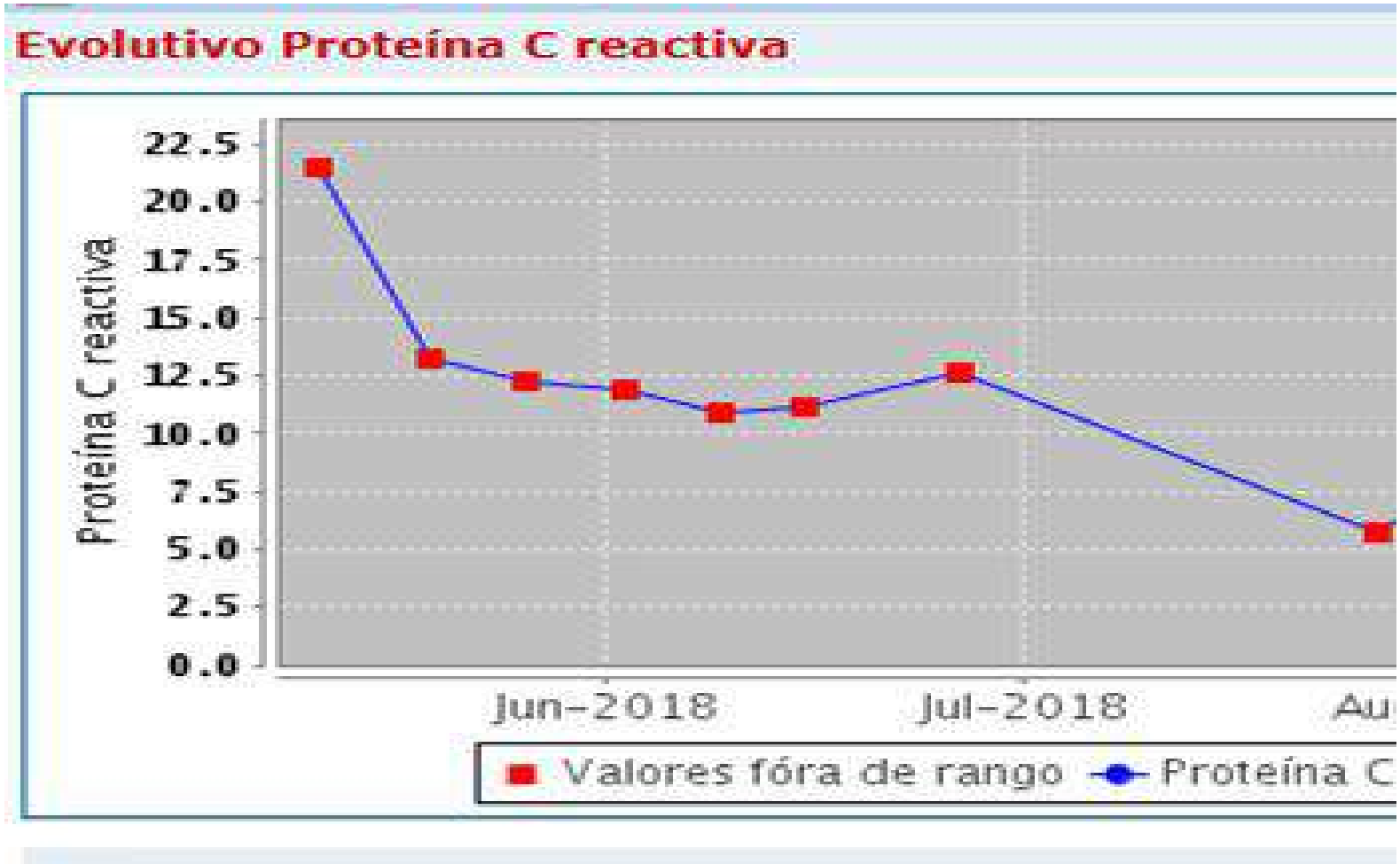

Annals of Vascular Surgery
Volume 29, Issue 7, October 2015, Pages 1451.e5-1451.e9

Case Report

The First Case of a Nellix Sac-Anchoring Endoprosthesis Removal for Aortoenteric Fistula

Emanuele Ferrero, Daniele Psacharopulo, Michelangelo Ferri, Giuseppe Berardi, Andrea Viazzo, Alberto Pecchio, Franco Nessi

JOURNAL OF ENDOVASCULAR THERAPY
A SAGE Publication
An official publication of the International Society of Endovascular Specialists

Case Report

Late Conversion After Sac Anchoring Endoprosthesis for Secondary Aortic Aneurysm Infection

Journal of Endovascular Therapy
2015, Vol. 22(5) 813–818
© The Author(s) 2015
Reprints and permissions:
sagepub.com/journalsPermissions.nav
DOI: 10.1177/1526602815601847
www.jevt.org
SAGE

Jip L. Tolenaar, MD, PhD[1], Leo H. van den Ham, MD[2], Michel M. P. J. Reijnen, MD, PhD[2], and Jean-Paul P. M. de Vries, MD, PhD[1]

EDITORIAL

New Technology Failures: Who to Blame or Time to be Cautious?

As Nellix is a completely new technology and not an evolution of an existing technology, one must not only see the potential and the opportunities, but also expect potentially completely new failure modes.

Vasc Endovasc Surg (2018) 56, 318—319

Junio 2017 → **Mayo** → **Junio** → **Agosto**

Aneurisma Ao abdominal

Endoprótesis Nellix

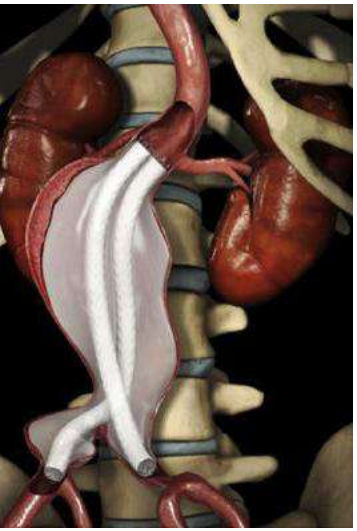

09/05/2018

Síndrome febril

Bacteriemia *S. intermedius*

Ertapenem

28/05/2018

PET-TC positivo

Punción colección periaórtica

Cultivo local: *S. intermedius*

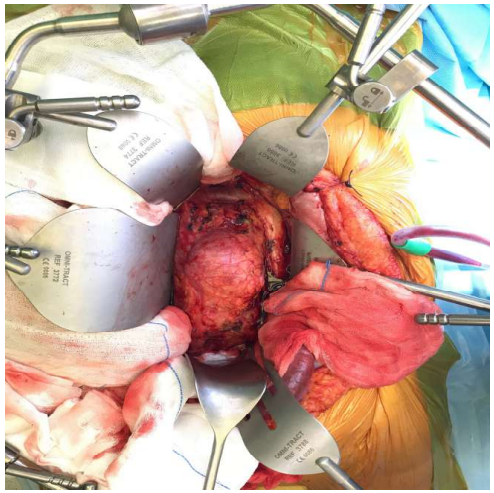

27/06/2018

Alta

Antibioterapia oral

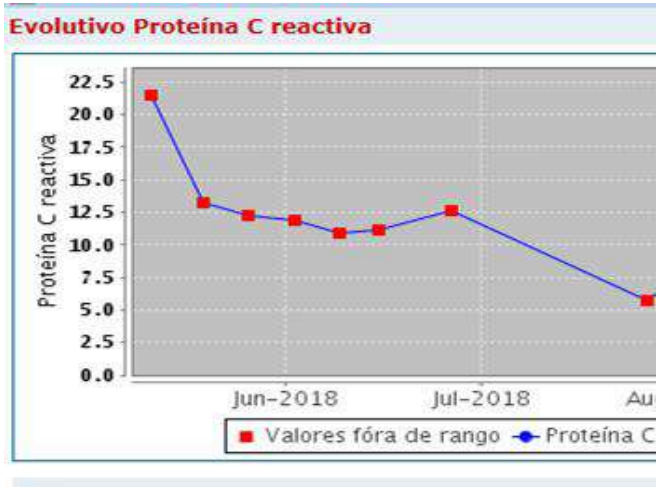

201 8

Septiembre

06/09/2018

Reingreso

Hemocultivos: (5/5)
S. intermedius

10/09/2018

Punción colección periaórtica (hemática)

Cultivo local: S. intermedius

Estudio de Sensibilidad Mostra: **Pus/Absceso COLECCIÓN PARAVERTEBRAL. PROTESIS AORTOBILIACA. ESPONDILODISCITIS**

Illase

Streptococcus intermedius (1)

Antibióticos	(1)
Ampicilina	**Sensible(.)**
Cefotaxima	**Sensible(.)**
Clindamicina	**Sensible(.)**
Eritromicina	**Sensible(.)**
Levofloxacino	**Resistente(.)**
Linezolid	**Sensible(.)**
Penicilina	**Sensible(.)**
Rifampicina	**Sensible(.)**
Tetraciclina	**Sensible(.)**
Trimetoprim-sulfametoxazol	**Sensible(.)**
Vancomicina	**Sensible(.)**
Tigeciclina	**Sensible(.)**

Observacións Streptococcus intermedius:

Se aislan abundantes colonias

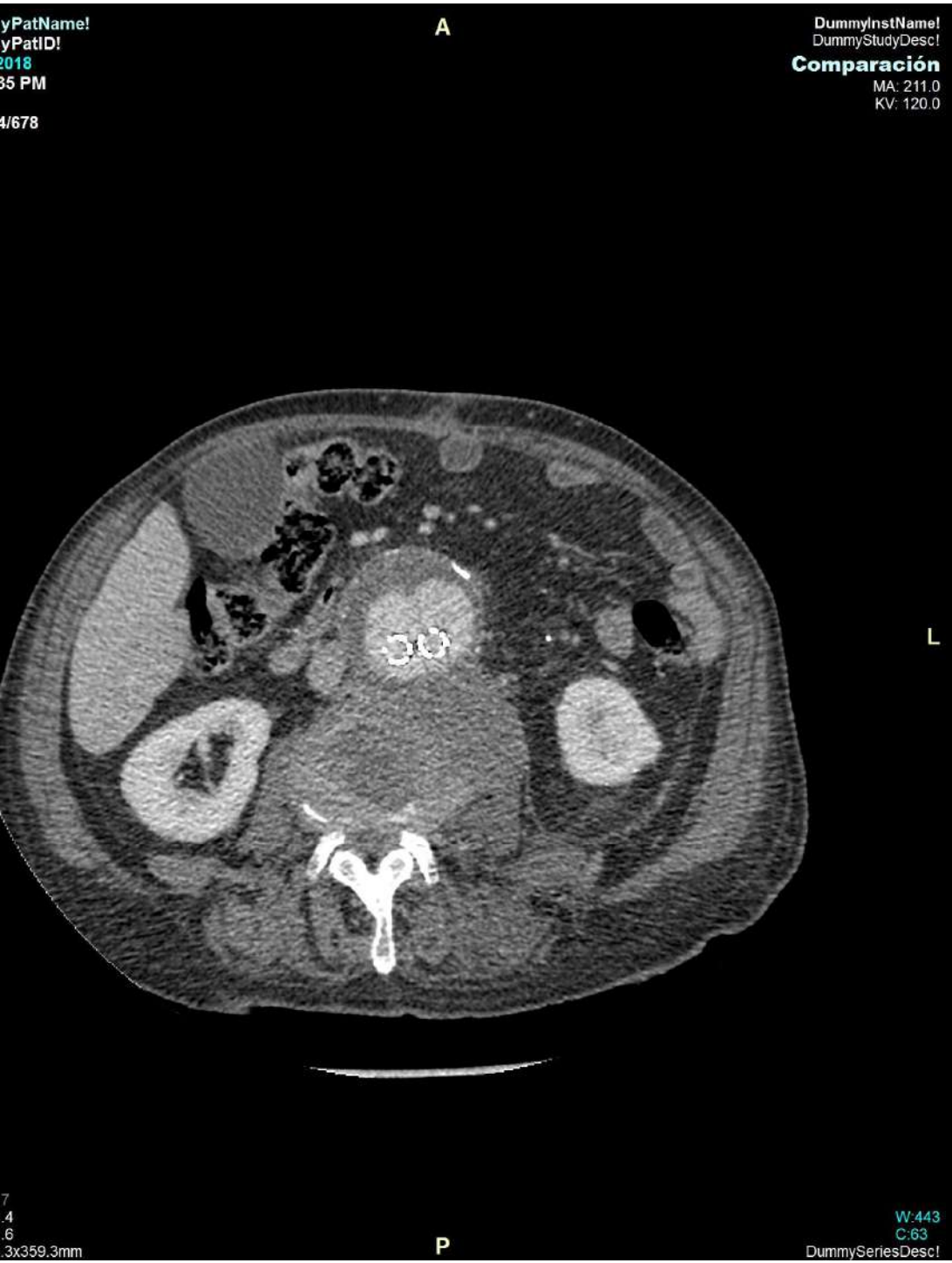
yPatName!
yPatID!
2018
35 PM
4/678
A
DummyInstName!
DummyStudyDesc!
Comparación
MA: 211.0
KV: 120.0
L
7
.4
.6
.3x359.3mm
P
W:443
C:63
DummySeriesDesc!

DummyPatName!
DummyPatID!
06-09-2018
06:10:35 PM
Se: 4
Im: 285/678
CA:
A
C
R
Zoom:2.9
BP:-210.3
ST: 0.6
CV: 351.6x359.3mm
P

tName!
ID!
M
A
DummyInstName!
DummyStudyDesc!
Comparación
MA: 226.0
KV: 120.0
L
9.2mm
P
W:377
C:60
DummySeriesDesc!

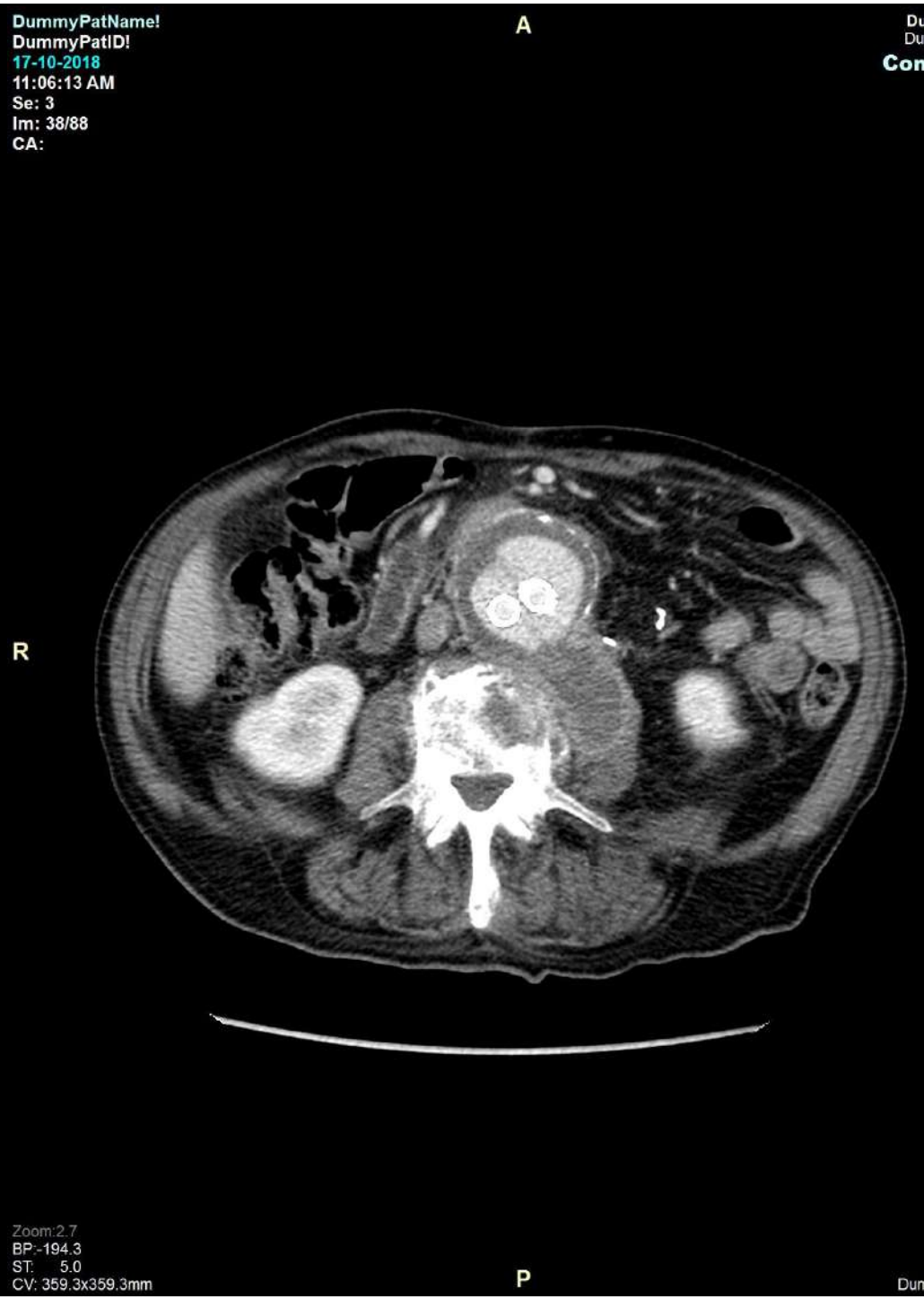
DummyPatName!
DummyPatID!
17-10-2018
11:06:13 AM
Se: 3
Im: 38/88
CA:
A
Du
Du
Com
R
Zoom:2.7
BP:-194.3
ST: 5.0
CV: 359.3x359.3mm
P
Dum



Interés del caso:

- Resaltar dificultad del diagnóstico
- Dificultad en relación con el tratamiento conservador
- Nuevos procedimientos = nuevos problemas



¡GRACIAS!

- S. Radiología Intervencionista (M. Marini)
- Servicio de Cirugía Vascular (CHUAC)
- S. Cirugía Cardíaca (Dr. V. Mosquera)
- S. Microbiología (M. Rodríguez)
- U. E. Infecciosas (Dr. L. Castelo, E. Sánchez)

INFECCIÓN DE PRÓTESIS ENDOVASCULARES
EXPERENCIA EN EL CHUAC
2011-2018

SERVIZO GALEGO de SAÚDE | Complexo Hosp Universitario A A Coruña

Indicación:

(N=11)

6 EVAR

- 4 Indicación primaria/AAA
- 2 De rescate-FAE

3 TEVAR

- 1 Disección Ao tipo B
- 2 AAT

2 Viabhan en AF

- 1 Indicación primaria
- 1 Rescate de pseudoaneurisma infeccioso roto

INFECCIÓN DE PRÓTESIS ENDOVASCULARES
EXPERENCIA EN EL CHUAC
2011-2018

SERVIZO GALEGO de SAÚDE | Complexo Hospitala Universitario A Coru A Coruña

Microbiología:

EVAR (6):

- *S. intermedius*
- *L. monocytogenes*
- *P. aeruginosa*
- *S. lugdunensis* + *S. epidermidis*

- *S. constellatus*
- *E. faecium*

] FAE

TEVAR (3):

- *S. lugdunensis*
- Cultivo negativo (1)
- Polimicrobiano (1) - FAE

	N (11)	Mortalidad al año
Tratamiento Quirúrgico	2	0
Tratamiento Conservador	9	4

- 2 EVAR rescate-FAE
  - Exitus a los 6 m.
- 1 TEVAR: aneurisma micótico (*Coxiella burnetii*)
  - FAE (1m)
  - Éxitus al ingreso